

IKSHA FOUNDATION

[HTTPS://IKSHAFUNDATION.ORG](https://ikshafoundation.org)

[HTTPS://WWW.FACEBOOK.COM/IKSHA-FOUNDATION](https://www.facebook.com/iksha-foundation)

[INFO@IKSHAFUNDATION.ORG](mailto:info@ikshafoundation.org)

ANNUAL REPORT
2020 - 2021



PUTTING OUR BEST FOOT FORWARD

Iksha Foundation turned 10 in 2020, a year that challenged us like no other before. While at the organisation level we grappled with losing some of our corporate donors to Covid relief, the families and the children we support suffered a lot more. Hurdles they faced include pass procurement to cross borders for treatment, shut down of public transport, longer wait time, RTPCR tests and PPE suits before every procedure.

Our gratitude to our donors who stood with us in these times and the hospitals who could recalibrate their SOPs to treat the children quickly before cancer took its toll. We appreciate the will of the parents who despite all odds stood their ground and ensure the children received treatment, albeit a little late.

We may not be out of the pandemic yet, but we have learnt some valuable lessons on being prepared for the unforeseen and protecting the children we support.

ABOUT

Retinoblastoma is a life-threatening eye cancer that affects children. The cancer grows from the retina, which is a sensory layer located inside the eye. Retinoblastoma is a silent tumour, most often detected too late to save the eye. In some children, the tumour affects both their eyes.

In early stages of the disease, the eye looks normal externally. As the cancer progresses, it might be observed by the parents as a white mass within the eye. This is often missed and the cancer progresses. Eventually, the eye becomes painful, red and swollen and spreads outside the eye and is life-threatening if it spreads to the brain.

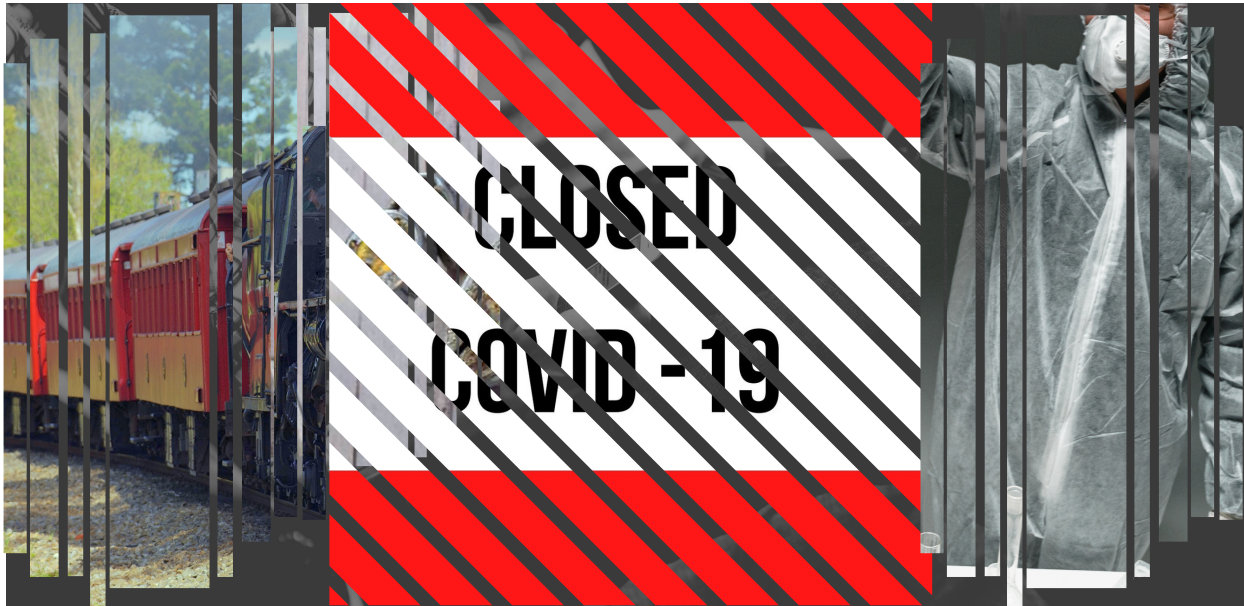We at Iksha, strive to provide support to Retinoblastoma patients with a multi-pronged approach.

- To provide financial support to the poor and underprivileged families of children with Retinoblastoma
- To ensure early diagnosis and timely treatment.
- To spread individual as well as societal awareness about Retinoblastoma and promote early detection
- To ensure quality treatment to these children.



Supporting Children with Eye Cancer

PANDEMIC PAINS



Covid-19 put the children with Retinoblastoma on a back-foot.

Upon diagnosis, most cases are scheduled for chemotherapy, occurring in 6 cycles, once every 3 weeks. Hospitals these kids visit were either in the same state or in a different state. Localised lockdowns, limited public transport, and sparse lodging made it hectic and stressful, risky, unaffordable and in many cases impossible for the parents to bring their kids for timely treatment.

Our team had to coordinate between authorities, hospitals and parents, in some cases in real time, to ensure the family reached the hospital or the location where their stay was arranged. Iksha with the help of friends and supporting network arranged for private transportation, police passes to travel the distance hassle-free and suitable accommodation where rations could be delivered.

The mandatory usage of PPE kits and Covid-19 tests increased the treatment cost, thereby decreasing the number of kids who could be supported this year. The lockdown and restrictions would have delayed diagnosis and timely treatment in many children.

Covid-19 also hindered education of the children Iksha is supporting. Luckily, neither children nor parents gave up and most of them attended online classes where possible. We had several requests for gadgets to attend classes.

Our goal this pandemic is to see the current children we support through their treatment with available funds. We will need to step up our fundraising because once travel norms are relaxed, more children with different stages of Retinoblastoma will reach hospitals for treatment.

WHERE WE ARE AT TODAY

Iksha successfully completed another financial year. With the spirit of service in the time of need, and the help of our amazing family of contributors, we continue to serve those most affected by Retinoblastoma in midst of a global crisis.

Iksha could only support the treatment of 13 new kids this year. In our 11 year of existence we have supported 175 kids in their battle with retinoblastoma.

A glimpse on Iksha kids treatment status!

Active treatment : 15 children are receiving treatment for active tumours (Chemotherapy / Laser / Cryotherapy / Topotecan / Brachytherapy) with an average treatment cost of Rs. 2 to 2,5 lakhs per child per year.

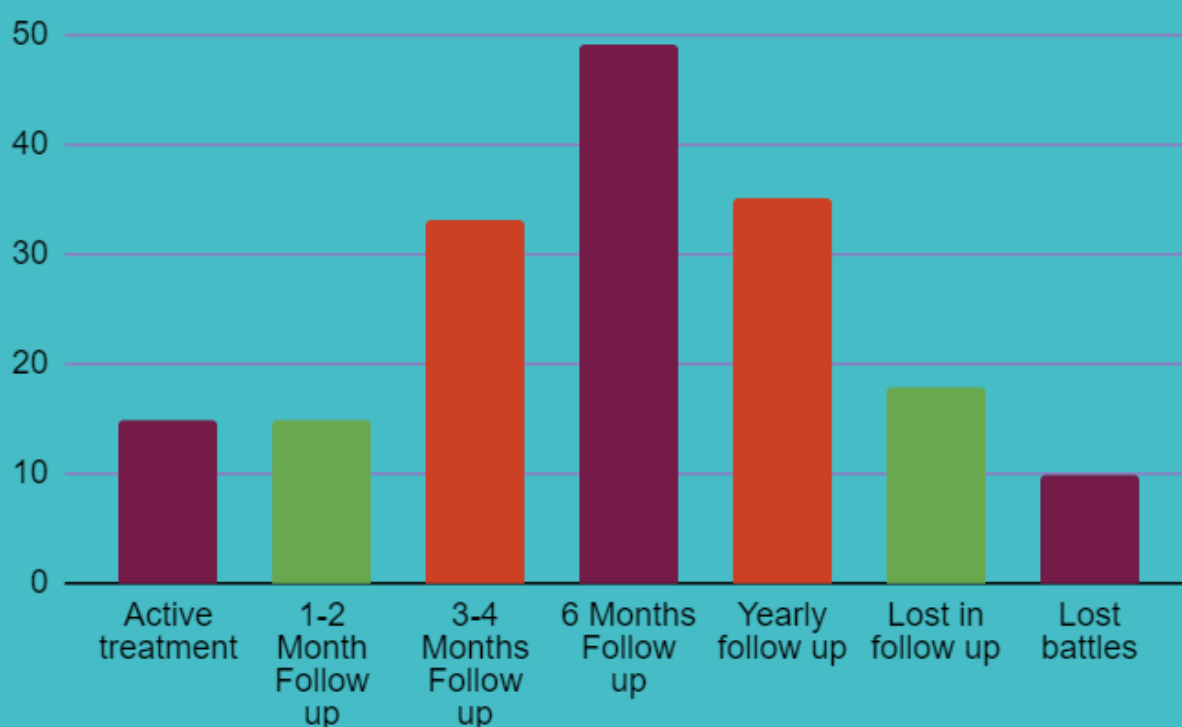
Under close observation : 48 children are under close observation. Treatment for the tumour is complete but they need close monitoring and testing to ensure early diagnosis of recurrence of tumour with an average treatment cost of Rs. 50,000 to 1 lakh per child per year.

Stable state : 58 children are in stable condition. They are either monitored half-yearly or yearly with an average treatment cost below Rs. 50,000 per child per year unless they develop cataract / Retinal vitrectomy or orbital mass with in the enucleated eye.

Survivors : 26 Children are declared Cancer (Retinoblastoma) Survivors if they are older than 8 years and have not had an active tumour for 4-5 years. Yearly followup cost and Custom made prosthetic eye change when needed.

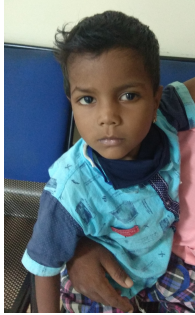Lost in follow up : 18 children were lost in follow ups in spite of availing best possible treatment, financial and moral support,

Lost battles : 10 children supported by us lost their battle to Retinoblastoma.



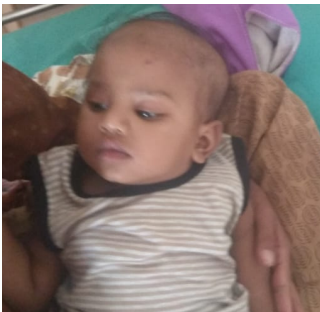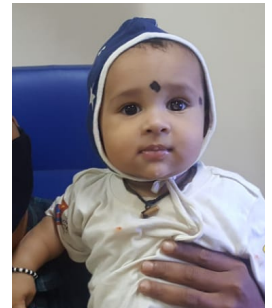
MEET OUR KIDS

SMILES OF IKSHA



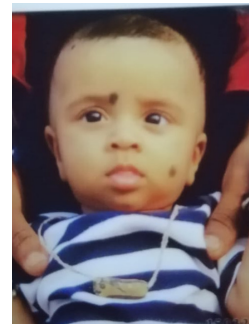
Bharath was diagnosed with unilateral Retinoblastoma in May 2020 at the age of 4. His left eye had to be enucleated post 5 cycles of chemotherapy and a custom-made ocular prosthetic eye had been implanted to ensure social acceptance. He is doing good and is now on a 3 months follow-up.

Dhruv's parents noticed white reflex in his left eye when he was 8 months old. He was diagnosed with bilateral Retinoblastoma. He completed his 6 cycles of chemotherapy and is receiving laser therapy every 4 weeks now. His right eye vision is good and the tumor is responding well to the treatment and the tumor in left eye is still active.



Dushyanth was 4 months old when parents noticed white reflex in his left eye. They consulted an eye specialist in Mysore. He was diagnosed with unilateral Retinoblastoma. They were referred to an eye hospital at Bangalore. Initially, the doctor suggested enucleation of his left eye. But parents wanted to wait till he finished his chemotherapy. He underwent 5 cycles of chemotherapy along with Laser and responded well to the treatment. Tumor had regressed. The doctor decided not to enucleate the eye and kept him under observation.


Noor's mother noticed a white reflex in her left eye and consulted a local doctor. An MRI was done and she was diagnosed with Unilateral Retino Blastoma. They came to an eye hospital at Bangalore by borrowing some money from friends and family and started with the treatment. Iksha now supports the child's treatment. She is receiving Chemotherapy for every 3 weeks and responding well to the treatment.



DONORS AND SPONSORS

THE TORCHBEARERS OF IKSHA'S SUCCESS STORY

The Pandemic wiped out all fundraising events that were planned for the year. Donors who have been an integral part of our journey continued to support us. Without their support we would not have been able to support the existing Iksha kids nor support any new child with retinoblastoma



Though at odds with a global crisis, RBL Bank continued to extend its support to Iksha consecutively for the 7th year. Through their contribution, RBL Bank supported the treatment of 97 children thus far. A monumental endeavour and a great positive during these times for children with retinoblastoma.

A BRIEF ON OUR FINANCES

UNAUDITED*

SOURCE OF FUNDS

Individual Donors
16.8%

Bank Interest
3.0%

CSR
80.2%

EXPENDITURE

Education

Admin 2.7%

Extra Support

3.4%

Treatment
86.6%

IKSHA FOUNDATION

We thank everyone
who've been a part of
our wonderful journey

CLICK HERE TO
SAVE A CHILD'S
VISION
DONATE NOW!